

ATYPICAL FOREIGN BODIES OF AERODIGESTIVE TRACT - CASE SERIES

Authors: Srishti Khera (1), Parul Verma (1), Sunil Kumar (2) Abhishek Bahadur Singh (3), Rajat Jain (4)

Authors Affiliations: (1) Senior Resident, (2) Professor, (3) Additional Professor, (4) Associate Professor, Department of Otorhinolaryngology and Head Neck surgery, King George's Medical University, Lucknow, U.P.- 226003

ABSTRACT

INTRODUCTION

Foreign bodies of the aero-digestive tract are a common but precarious entity. Pediatric and geriatric populations are particularly at risk.

Materials and Methods: Clinical features can range from asymptomatic to life-threatening and depend on the nature, site, size and duration of foreign body impaction.

CONCLUSION

With advancements in technology and healthcare, multiple modalities for foreign body removal are now available. However, foreign body removal using rigid endoscopes is still the most widely used, considering factors like patient comfort and safety as well as direct visualization of the foreign body.

KEYWORDS

Foreign body; aspiration; ingestion; aero-digestive tract

INTRODUCTION

Although foreign bodies can be encountered in all areas of ENT, foreign bodies of the aero-digestive tract are of special importance due to the risk of life-threatening complications and expertise required in their management. Foreign bodies of the digestive tract mainly present with dysphagia and throat pain. However, a foreign body in the upper two-thirds of esophagus can cause airway compression in children and may

present with cough, wheezing or symptoms of respiratory distress. Many times, the patient may be asymptomatic and history of witnessed foreign body intake may be only presenting complain.¹

Radiological investigations, mostly X-Rays play a crucial role in the diagnosis of an aero-digestive foreign body. CT scan is useful in complicated cases or in case of radiolucent foreign bodies. Rarely, a diagnostic endoscopy can be performed solely on the basis of clinical history and suspicion of foreign body.²

Radiography not only helps in establishing a diagnosis but also helps to rule out complications. A coin in the esophagus presents as a circular object in AP view and linear on lateral view, as opposed to a coin in the trachea, which shows a reverse pattern. A lithium ion battery appears as double contour sign on AP view and in lateral view, the step of the battery can be seen. Signs like subcutaneous emphysema, retro-esophageal air shadow, pneumo-thorax and pneumo-mediastinum are suggestive of a perforation.^{1,3}

Rigid oesophagoscopy is the method of choice for removal of digestive tract foreign bodies. For esophageal foreign bodies, endotracheal intubation is important, since it prevents aspiration of foreign body and reduces tracheal compression caused by the oesophagoscope.

Foreign body aspiration as well as ingestion can be extremely dangerous. Educating parents and caregivers regarding danger signs and appropriate safety measures, the need for age-appropriate toys and emergency management is crucial.³

CASE SUMMARY

CASE 1:

A five-year-old female presented to our side with complain of accidental aspiration of foreign body while undergoing a dental procedure 4 hours ago, followed by off and on cough since then. Patient had no complain of difficulty in breathing or swallowing, no complain of change in voice, no respiratory distress. An X-ray was taken, which was suggestive of a sharp radio-opaque foreign body in the left main bronchus (Image 1) Patient was posted for urgent bronchoscopy and removal of foreign body and a dental file (image 2) was removed from the left bronchus, with special care intra-operatively to avoid any trauma to surrounding mucosa.

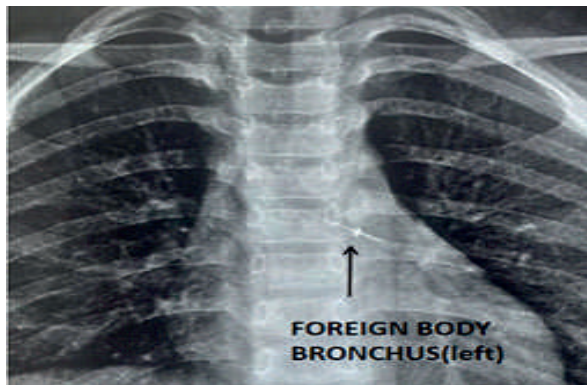


Image 1: X-ray chest showing a radio-opaque foreign body in left main bronchus.

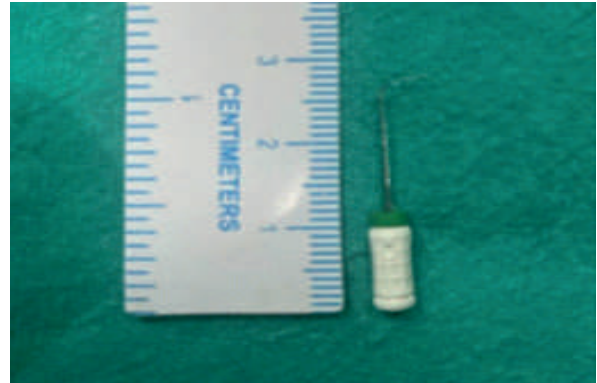


Image 2: Foreign body (dental file) after removal

CASE 2:

A one and half year-old child came to our side with complain of accidental ingestion of foreign body (ear ring) while playing 2 hours ago, followed by irritability and refusal to feed since then. Patient had no complain of difficulty in breathing or change in voice or hoarse cry. X-ray neck was suggestive of radio-opaque foreign body with one sharp end and other blunt end in the oesophagus (Image 3). Patient was posted for urgent oesophagoscopy and sharp end of foreign body was found embedded in the mucosa, from where it was dislodged followed by removal of stud earring (Image 4), to avoid further mucosal injury.

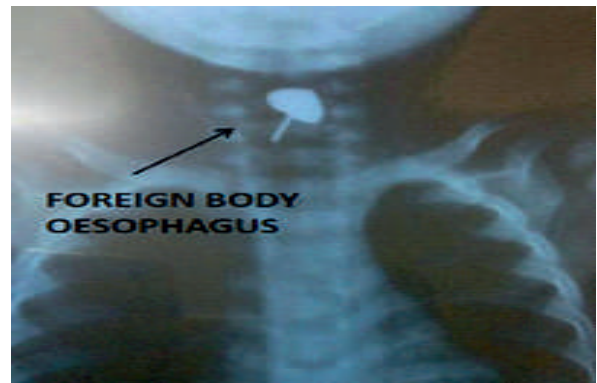

Image 3: X-ray neck showing a foreign body with sharp end directed caudally and blunt end directed cranially.

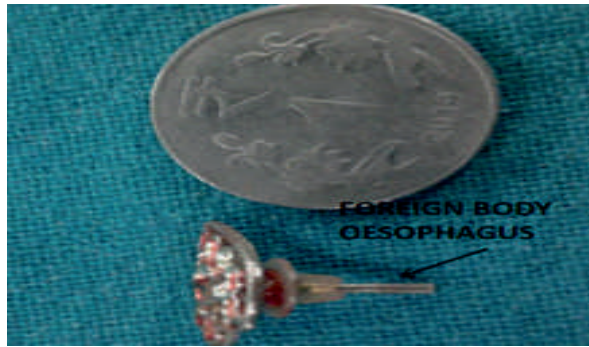


Image 4: Foreign body (stud earring) after removal.

CASE 3:

A 6-year-old male presented to our side with complain of accidental aspiration of baby lemon 2 days ago followed by difficulty in breathing since then. On auscultation breath sounds were absent on right side. A chest X-ray was taken which revealed homogenous radio-opacity due to right lung white out (Image5). Patient was posted for urgent bronchoscopy and foreign body (baby lemon) was removed from right main bronchus.

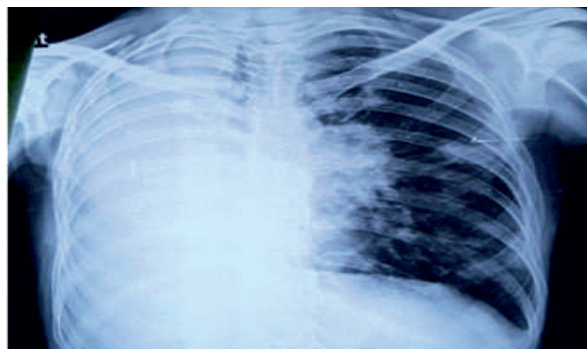


Image 5: X-ray chest showing homogenous right lung opacity

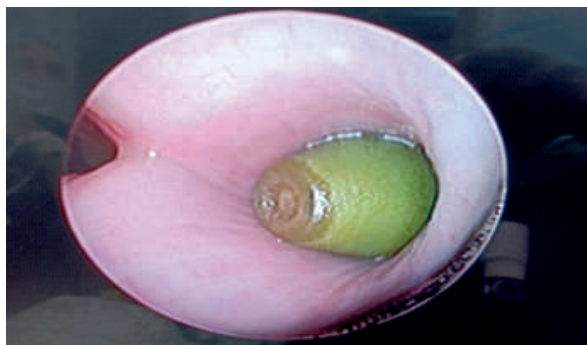

Image 6: Intra-operative image of foreign body causing complete obstruction of right main bronchus

Case 4:

A 29-year male presented to our side with accidental aspiration of LED bulb 12 hours ago, followed by off and on cough since then. Patient had no complains of difficulty in breathing or change in voice. On examination, the patient was hemodynamically stable and had no signs of respiratory distress. An X-ray in lateral view was suggestive of sharp foreign body with prongs directed cranially in left main bronchus (Image 7). Patient was posted for urgent bronchoscopy and LED bulb (Image 8) was removed from left main bronchus.

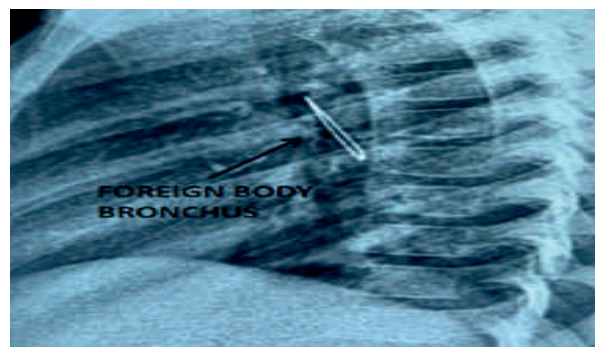


Image 7: X-ray chest lateral view showing a foreign body with prongs directed cranially.




Image 8: Foreign body (LED bulb) after removal.

CASE 5:

A 21-year-old female presented to our side with complain of ingestion of foreign body (blade) 2 hours ago, followed by pain in throat and blood

stained vomiting. An X-ray neck and chest was suggestive of radio-opaque linear foreign body in oesophagus at the level of C6-T2 vertebrae (Image 9). Patient was posted for urgent oesophagoscopy and removal of foreign body (blade) (Image 10) was done. Significant mucosal injury was seen intra-operatively for which Ryle's tube insertion was done and patient was kept on nasogastric feeds for 5 days and patient was discharged with proper medication.

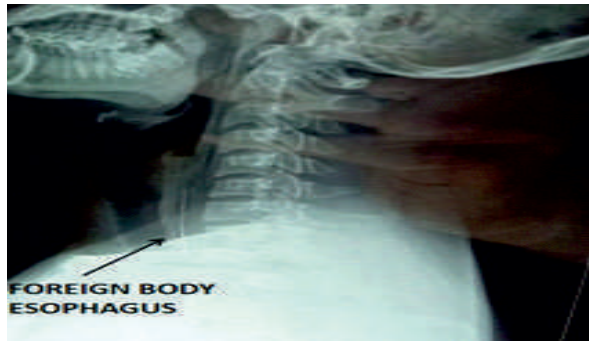

Image 9: X-ray neck lateral view showing linear radio-opaque foreign body in the oesophagus at the level of C6-T2 vertebrae.

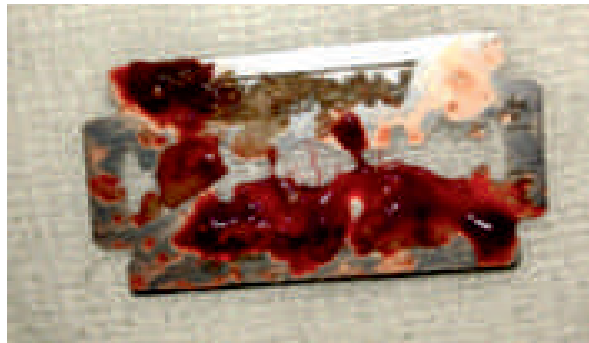

Image 10: Foreign body (blade) after removal

CASE 6:

A 12-year-old female presented to our side with sudden onset hoarseness of voice. On detailed history, there were no complaints of fever, dysphagia and dyspnea. An X-ray neck was undertaken, which was suggestive of radio-opaque foreign body in the airway at level of C3-C6 vertebrae (Image 11). Patient was posted for urgent laryngoscopy and foreign body (safety pin) was visualised between the vocal cords and

was removed. (Image 12)

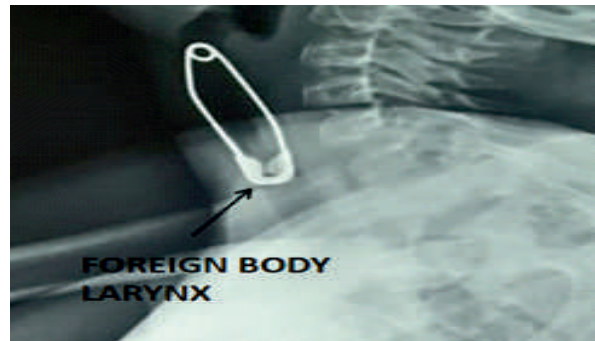


Image 11: X-ray neck lateral view showing radio-opaque foreign body in the airway at level of C3-C6 vertebrae



Image 12: Foreign body (safety pin) after removal.

CASE 7:

A 10-month old child presented to our side with accidental ingestion of foreign body (sewing needle) 4 hours ago followed by refusal to feed and irritability since then. X-ray was suggestive of sharp radio-opaque linear foreign body in the oropharyngeal area (Image 13). Foreign body was embedded in base of tongue, which was removed using direct laryngoscope.

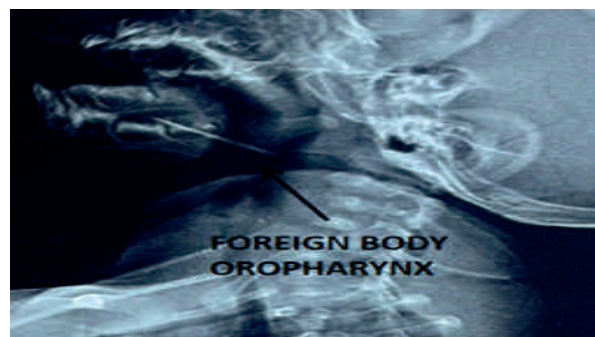


Image 13: X-ray showing linear radio-opaque linear foreign body in the oropharyngeal area.

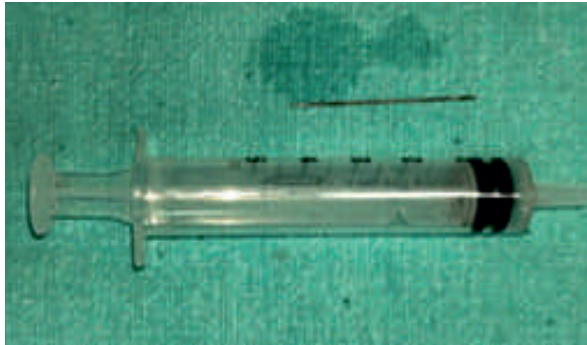

Image 14: Foreign body (sewing needle) after removal.

CASE 8:

A 16-year-old male presented to our side with complain of accidental aspiration of foreign body (spring coil) 14 hours ago, followed by off and on cough since then. Patient was hemodynamically stable and had no signs of respiratory distress. A lateral view X-ray was taken, which was suggestive of a radio-opaque coiled foreign body in bronchus (Image 15). Patient was posted for bronchoscopy and a spring coil was removed from the bronchus (Image 16). Post-operative period was unevenful and patient was discharged next day with supportive medications.

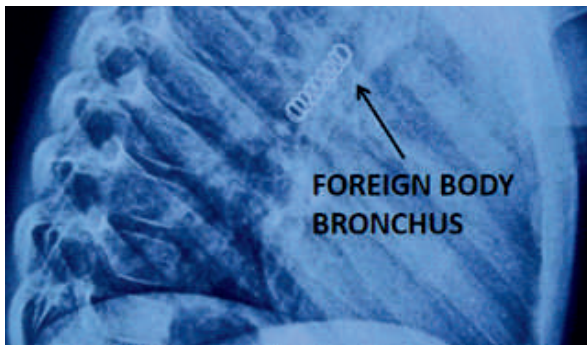


Image 15: X-ray chest lateral view showing radio-opaque coiled foreign body in bronchus




Image 16: Foreign body (spring coil) after removal.

DISCUSSION

Foreign body of the aero-digestive tract is a common ENT emergency. Foreign bodies of the digestive tract are twice as frequent as those in the airways. Amongst the digestive tract, upper oesophagus is the most common site of impaction due to narrow cricopharynx and weaker peristalsis in the upper oesophagus. In case of aspirated foreign bodies, right main bronchus is more commonly affected because of its straighter trajectory in relation to the trachea and wider and shorter dimensions, which was also observed in our cases 3,4,5,6,

Although patients of any age group can be affected, the incidence is higher among extremes of age. Children under 5 years of age have underdeveloped gag reflex and impaired neuromuscular coordination between pharynx and larynx, hence foreign body aspiration is more common than ingestion.^{6,7}

Coins are the most commonly seen foreign bodies in digestive tract. Unusual foreign bodies like magnets, batteries, small toys, jewellery, bones and dentures can be encountered. Aspirated foreign bodies include both organic and inorganic materials, however organic materials like nuts, dried fruits and seeds are seen more frequently.^{1,6}

Clinical presentation depends on the age of the patient, size, location and duration of the foreign

body and can range from asymptomatic to life-threatening.

- Drooling and poor feeding are usually the chief presenting complaints in infants with ingested foreign bodies, which was seen by us in case 7, where the patient presented with irritability and refusal to eat.
- Older children and adults typically present with irritability, odynophagia, dysphagia and chest pain.
- Rarely, respiratory symptoms such as dyspnea and cough can be seen due to compression or irritation of the respiratory tract due to micro-aspiration of saliva. In our series, difficulty in breathing was encountered in case 3 where there was a complete obstruction of right main bronchus.^{1,3,4}

While foreign bodies in the esophagus cause persistent symptoms until they're removed; foreign bodies in the airway typically present with an asphyxial period followed by an asymptomatic period, which often leads to a delay in diagnosis.

In our case series, the most common presenting complaint was throat pain, irrespective of the site of lodgement. In one case, foreign body blade ingestion (Case 5), patient presented with hematemesis, due to severe mucosal injury.

Diagnosing a foreign body in aero-digestive tract can be challenging due to a combination of non-specific symptoms and a lack of clear history. In such cases, imaging is of utmost importance.¹ An X-ray must be undertaken in any patient suspected of having an aero-digestive tract foreign body especially in radio-opaque foreign bodies as in seven cases. In case 3, although a foreign body wasn't visualised on X-ray, the findings indirectly pointed towards an obstruction, which can be seen in case of foreign body.

- An X-ray lateral view not only helps in distinguishing between esophageal and tracheo-bronchial foreign bodies, but can also

detect multiple foreign bodies and perforation, suggested by retro esophageal air.

- CT scan is recommended in case of complications or when a radiolucent foreign body is suspected.
- However, foreign bodies can be missed on radiological examination and in such cases a diagnostic endoscopy should be performed.²
- Rapid diagnosis and treatment is crucial in case of aerodigestive tract foreign bodies. It decreases patient morbidity and risk of further complications.⁵

The method of retrieval of foreign bodies depends on multiple factors like airway obstruction, the nature and location of the foreign body, age and overall health of the patient. Conventional practice of removal of foreign body under direct visualization, using rigid endoscope is the safest and the most reliable method.⁸ In our series, all the cases were managed in a similar manner where the foreign body was removed using a rigid bronchoscope or oesophagoscope of an appropriate size, depending on the site of lodgement. However, some cases require special care. Sharp foreign bodies and lithium ion batteries require immediate intervention because of high chances of impending complications. Intra-operatively, different types of foreign bodies require different instruments and tricks; sharp ones should be handled in a way that avoid mucosal injury as seen in case no. 1,2,5 and 7. Wide-mouthed forceps may be needed for larger foreign body like in case 3.

Complications can occur due to delay in diagnosis or treatment, or due to the foreign body itself. Large objects in the airway and complications such as esophageal perforations, mediastinitis and aorto-oesophageal fistula can be fatal. Sharp foreign bodies can penetrate the mucosa and migrate extraluminally. While the ultimate aim is foreign body removal, the treatment plan may vary according to extent of

injury and complications.² A nasogastric tube insertion may be required in case of mucosal injury or corrosive foreign bodies, as in case 5.

Considering the high morbidity and mortality rates of aero-digestive foreign bodies, public awareness and education is extremely important, with special emphasis on preventive measures. Parents and caregivers should be trained regarding low threshold for suspicion, danger signs and the importance of early intervention.

CONCLUSION

Foreign bodies in the aero-digestive tract are common emergencies, particularly affecting children under five years and the elderly. FBs are more frequently found in the digestive tract, especially in the cervical esophagus, due to anatomical and functional factors. In the airway, the right main bronchus is more commonly involved than left. Coins and organic items are the most commonly ingested and aspirated objects respectively but atypical foreign bodies are also encountered. Clinical presentation varies by age and foreign body characteristics. Diagnosis can sometimes be challenging due to non-specific symptoms and unclear history. X-rays are essential, but CT scans or endoscopy are reserved for complicated or inconclusive cases. Timely intervention is vital to avoid serious complications. Rigid endoscopy remains the safest and most effective method for removal. Public education and parental awareness are key in prevention, emphasizing early recognition and prompt medical attention.

Acknowledgements:

It is a privilege to express my feelings of deep gratitude to my esteemed teachers Prof. Anupam Mishra (Prof & Head) Prof. Veerendra Verma (Professor) ,Prof. H.P. Singh (Professor) and Dr. Manish Chandra (Additional Professor) for their continuous inputs, clinical cooperation and platform to publish such a case report.

Ethics Approval and Consent for Participation:

Obtained from Institutional Ethics Committee.

A written informed consent for publication of the patient's details and images was obtained from the patient or patient's guardian.

Financial Support: None

Conflict of Interest: The author declares that they have no conflicts of interests.

REFERENCES:

1. Mathew RP, Liang TI, Kabeer A, Patel V, Low G. Clinical presentation, diagnosis and management of aerodigestive tract foreign bodies in the paediatric population: Part 2. SA J Radiol. 2021 Mar 23;25(1):2027
2. Hariga I, Khamassi K, Zribi S, Amor MB, Gamra OB, Mbarek C, Khedim AE. Management of foreign bodies in the aerodigestive tract. Indian J Otolaryngol Head Neck Surg. 2014 Jan;66(Suppl 1):220-4
3. Rodríguez H, Cuestas G, Botto H, Nieto M, Cocciaglia A, Gregori D. Cuerpos extraños en el esófago en los niños: Serie de casos [Foreign bodies in esophagus in children: case series]. Arch Argent Pediatr. 2013 Jun;111(3):e62-5.
4. Srivanitchapoom C, Yata K. Complicated cases in foreign bodies of the ear, nose, and throat: a case series. Colomb Med (Cali). 2024 Jun 30;55(2):e2045837
5. Gupta R, Poorey VK. Incidence of foreign bodies in aerodigestive tract in vindhya region: our experience. Indian J Otolaryngol Head Neck Surg. 2014 Jun;66(2):135-41
6. Berdan EA, Sato TT. Pediatric Airway and Esophageal Foreign Bodies. Surg Clin North Am. 2017 Feb;97(1):85-91.
7. Adeoye PO, Afolabi OA, Omokanye HK, Olaoye I, Akanbi OR, Segun-Busari S, Adesiyun OAM, Ige OA, Akiode AO, Wuraola OA, Abdulkadir MB, Oni JO. Foreign bodies in the aerodigestive tract: time for comprehensive preventive measures. Afr Health Sci. 2022 Jun;22(2):369-76.
8. Daultrey, C. R., & Howe, D. G. (2016). An

alternative approach to pharyngeal and hypopharyngeal foreign body removal in the clinic: a successful five case series. *Clinical Otolaryngology*, 42(3), 777–9.

***Corresponding Author**

Srishti Khera 1*

Senior Resident

Department of Otorhinolaryngology and Head Neck Surgery, King George's Medical University, Lucknow, U.P.- 226003

Email ID- drsrishtikhera@gmail.com

Phone no.- 8588095935

ORCID ID- 0000-0002-2625-889X

Copyright: © 2025- Srishti Khera, etal; This is an open-access article distributed under the terms of the Creative Commons Attribution License, which permits unrestricted use, Distribution, and reproduction in any medium.

How to cite this article

Srishti K. etal: Atypical Foreign Bodies of Aerodigestive Tract - Case Series -- UPJOHNS; June 25; 13(2); page: 40-47



This work is licensed under a Creative Commons Attribution 4.0 International License
Copyright © 2020 –UPJOHNS